

## Chapter 1

# Endobronchial Foreign Body Induced Obstructive Pneumonitis Mimicking a Tumour

Junaid Hussain<sup>1\*</sup>

<sup>1</sup>*Kims Sreechand, Kannur, Kerala, India.*

---

## Abstract

Foreign body aspiration (FBA) is infrequently reported in the adult population, with major risk factors including advancing age, intoxication, and disorders of the central nervous system etc. Here, I present a case of FB aspiration in a patient who was referred in view of squamous metaplasia? Carcinoid tumour suspicion in bronchoscopic BAL cytology report, which on our repeat bronchoscopy and biopsy under short GA found out to be a foreign body Granuloma, causing obstructive pneumonitis, which was trapped in right lower lobe bronchus causing surrounding bronchial mucosa oedema and inflamed. We ordered a repeat CECT scan of chest which is almost after 6 months of previous CT, which showed patchy consolidation with cut off sign in right lower lobe posterior and medial basal segment with size of patch appears to be stable compared with old CT. Bronchoscopy was performed, revealing oedematous and inflamed basal bronchus and on careful inspection removed a small foreign body and took biopsy from inflamed bronchial mucosa. Histopathologic analysis of the tissue sample revealed the presence of an aspirated foreign body with squamous metaplasia and granulation of the respiratory epithelium. Adult FBA presenting as endobronchial tumour is rare and always inspect airways carefully when suspecting endobronchial tumour and rule out an obstructive pneumonitis first..

**Keywords:** FBA- Foreign Body Aspiration, LMA- Laryngeal Mask Airway, GA- General Aneasthasia, BAL- Broncho Alveolar Lavage, CT- Computed Tomography.

---

## 1. Introduction

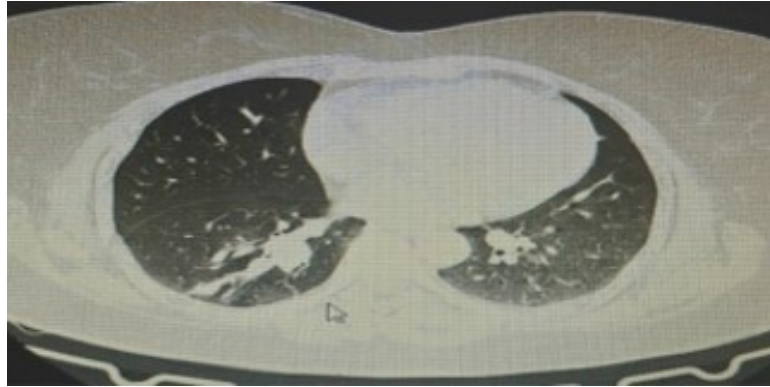
FBA is usually encountered in pediatric populations. Although the majority of cases can be diagnosed correctly in the early period, some patients can be misdiagnosed with pneumonia, laryngitis, and with asthma in children [5,6] or chronic obstructive pulmonary disease, asthma, sputum impaction, and suspicious lung cancer in adults [7]. Once an accurate diagnosis of airway FB is determined in adults, the FB can be successfully extracted using flexible bronchoscopy, and this approach is associated with a success rate of 61–100%. However, it is important to use the appropriate equipment to increase the success rate. Herein, we describe a case of an airway FB that mimicked an endobronchial tumor in cytology report in an adult, which was successfully removed under flexible bronchoscopy with rat tooth grasping forceps.

## 2. Case Presentation

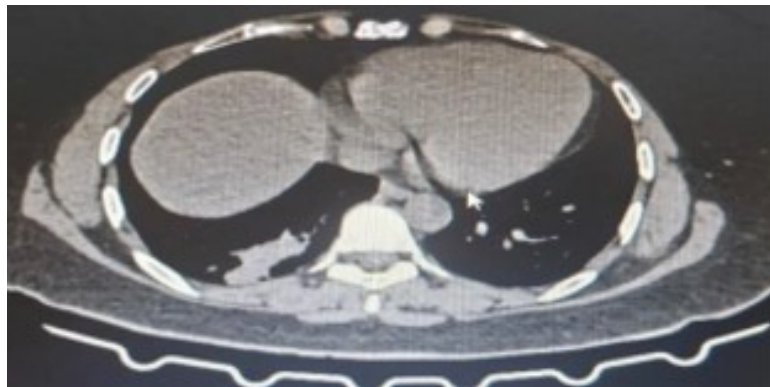
A 52-year-old lady with no comorbidities and no smoking history presented with c/o chronic cough, not associated with fever or weight loss or loss of appetite, also c/o mild shortness of breath, came to OPD with reports of previous bronchoscopy done in another hospital with biopsy and BAL cytology reports, which was suggestive of? Squamous metaplasia? Carcinoid tumour. On physical examination, chest: decreased breath sound right infrascapular area, no additional sounds. BP 120/80mmhg, PR 84/min, Spo2 was 94% room air. Other systemic examinations were normal.

### 3. Imaging

A REPEAT CECT CHEST SHOWED “Patchy consolidation involving posterior basal and medial basal segment of right lung lower lobe. Mild bronchiolar prominence in this region with cut-off of few of the subsegmental bronchioles within the consolidation. Compared to previous CT films dated 30-12-2024 (done outside), the consolidatory patch appears to be fairly stable in size and extent”.

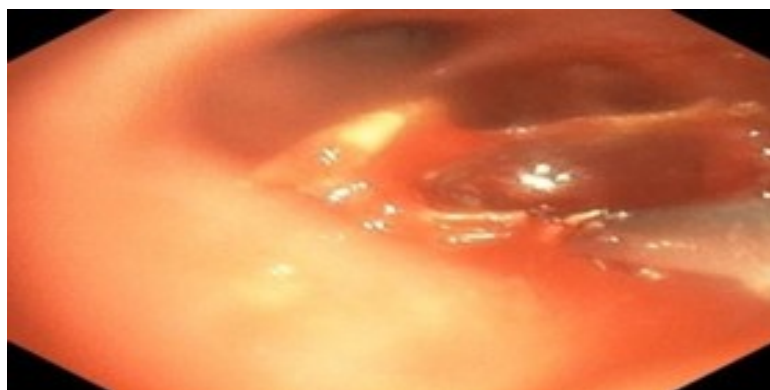


**Figure 1:** Lung parenchymal window s/o patchy consolidation of right posterior basal segment



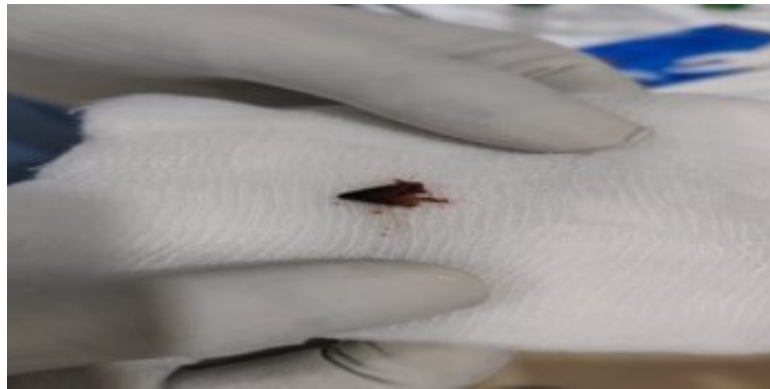**Figure 2:** Mediastinal window confirming the above lesion

**Bronchoscopy Done Under Short Ga Via LMA Tube:** S/o right lower lobe posterior basal segment filled with thick purulent secretion which was cleared by administering saline and suctioning. Which revealed an edematous and inflamed bronchial mucosa and multiple forceps biopsy taken. Finally noticed a small conical reddish brown foreign body obstructing the bronchial lumen and which was removed by rat tooth biopsy forceps Figure 3 and 4. Both sample sent for HPE.



**Figure 3:** A conical shaped foreign body removing with rat teeth biopsy forceps in bronchoscopy

**Histopathology:** HPE s/o bronchial mucosa with acutely inflamed granulation tissue, squamous metaplasia and FB materials. Fragments of bronchial mucosa showing focal squamous metaplasia and dense neutrophilic infiltrate. No evidence of malignancy.



**Figure 4:** Removed foreign body, a conical shaped plastic

## 4. Discussion

Foreign body aspiration (FBA) is a relatively uncommon phenomenon in the adult population. Indeed, a large recent retrospective study by Ulas et al. determined that only 11.7% of FBA cases were seen in adult patients (>18 years old) [1]. Aspiration in the pediatric population, however, is the fourth leading cause of accidental mortality in patients under the age of three years [2]. Despite its relative infrequency, the incidence of adult deaths due to FBA increases with advancing age beyond the sixth decade [3]. Additional risk factors in the adult population include trauma, altered mentation as a result of sedative or alcohol use, or primary neurologic disorders such as stroke or seizure disorder.

Foreign body aspiration (FBA) is a relatively uncommonly encountered in the adult population. A large retrospective study by Ulas et al. determined that only 11.7% of FBA cases were seen in adult patients (>[1]. Aspiration in the pediatric population, however, is the fourth leading cause of accidental mortality in patients under the age of three years [2]. Despite its relative infrequency, the incidence of adult deaths due to FBA increases with advancing age beyond the sixth decade. Additional risk factors in the adult population include trauma, altered mentation as a result of sedative or alcohol use, or primary neurologic disorders such as stroke or seizure disorders [3,4].

The most common symptoms associated with FBA in adults include a sudden onset of choking, coughing dyspnea, fever, hemoptysis, and wheezing [1,5,6]. The type of aspirated object varies depending on the medical environment and cultural practices of the patient population [5,8].

Clinical manifestations of FB aspiration can vary, depending on the size of the FB and the location where it becomes lodged [8,9,10]. In addition, atelectasis, pneumonia, respiratory distress, bronchiectasis, cardiopulmonary arrest, and pneumothorax can occur as complications of airway FB [9].

The right bronchus intermedius is the most common site for airway impaction with adult FBA, which is likely secondary to its relatively vertical configuration. The left and right main stem bronchi are the second and third most common sites for aspiration, respectively.

If diagnosis is delayed, unrecognized and retained pulmonary foreign bodies can lead to severe complications [11]. Foreign bodies that remain in the bronchi for an extended period can irritate the local mucosa, causing inflammation and oedema, leading to granulation tissue proliferation that embeds and covers the foreign body and obstructs the bronchial openings, potentially causing pulmonary inflation insufficiency or atelectasis [12]. The granulation tissue anchors the foreign body to the airway walls, making removal more difficult and carrying risks of bleeding and airway damage. Furthermore, impaired drainage of secretions from the distal airways can lead to recurrent infections at the same site, resulting in obstructive pneumonia [13].

The diagnosis of FBA is typically achieved with a combination of detailed history-taking, diagnostic imaging, and bronchoscopy. Standard chest radiography is the initial imaging modality of choice in cases of suspected aspiration. However, the variable radiopacity of aspirated objects results in the inconsistent sensitivity reported in the literature, ranging from 8% to 80%. Secondary signs of FBA on radiography such as obstructive atelectasis, focal post-obstructive consolidation, and air trapping can be useful to reinforce clinical suspicion and direct further imaging or interventions [5,7].

A chest CT may be performed following initial radiography to identify radiolucent foreign bodies not seen on X-ray as well as to provide anatomic detail for procedural planning. Interestingly, the patient in the case presented here underwent routine annual cancer screening CT for lung cancer, which is when the aspirated foreign body was incidentally discovered. Jang et al. found that CT studies reliably identify tracheobronchial foreign bodies when compared to standard radiography, with greater than 60% sensitivity [5]. When a foreign body is not readily identified, secondary findings such as airway obstruction, mucus plugging, bronchial wall thickening, air trapping, post-obstructive atelectasis, or pneumonia are suggestive of FBA and warrant further bronchoscopic evaluation following CT.

Once FBA is identified or suspected with corroborative clinical history and imaging findings, bronchoscopy is the next step in management for foreign body removal. Flexible bronchoscopy is the favoured procedure in the adult population as it produces less patient discomfort, may be performed under light sedation or short GA via LMA and uniquely allows access to the distal and peripheral airway.

## 5. Conclusion

FB Aspiration is relatively uncommon in the adult population, particularly in the absence of known risk factors such as trauma, intoxication, or primary neurologic disorders. Here, we present a unique case of an aspirated foreign body incidentally identified on low-dose chest CT to highlight a potential pitfall for the interpreting radiologist. As updated recommendations for lung cancer screening result in a broader population now eligible for low-dose chest CT, it is important for radiologists to recognize alternative entities that may mimic malignancy on traditional and hybrid imaging modalities. This case also highlights, carefully examine airways for presence of any foreign body, removing granulation tissue to extract the foreign body and relieve airway obstruction requires a lengthy procedure involving multiple instruments and

can be highly unpleasant for the patient, making it unsuitable for routine bronchoscopy. Therefore, performing the removal under general anaesthesia with tracheal intubation/ LMA is a safe and [14] reliable method. If diagnosis is delayed, unrecognised and retained pulmonary foreign bodies can lead to severe complications [11]. Foreign bodies that remain in the bronchi for an extended period can irritate the local mucosa, causing inflammation and oedema, leading to granulation tissue proliferation that embeds and covers the foreign body and obstructs the bronchial openings, potentially causing pulmonary inflation insufficiency or atelectasis [12].

## Declaration

**Funding:** This study received no external funding.

**Informed Consent:** Informed consent was taken from the patient.

**Conflict of Interest:** The Author declare no conflict of interest.

## References

- [1] Ulas AB, Aydin Y, Eroglu A: Foreign body aspirations in children and adults. *Am J Surg.* 2022, 224:1168-73. 10.1016/j.amjsurg.2022.05.032.
- [2] Altkorn R, Chen X, Milkovich S, et al.: Fatal and non-fatal food injuries among children (aged 0-14 years). *Int J Pediatr Otorhinolaryngol.* 2008, 72:1041-6. 10.1016/j.ijporl.2008.03.010.
- [3] Rafanan AL, Mehta AC: Adult airway foreign body removal. What's new?. *Clin Chest Med.* 2001, 22:319-30. 10.1016/s0272-5231(05)70046-0.
- [4] Cunanan OS: The flexible fiberoptic bronchoscope in foreign body removal. Experience in 300 cases. *Chest.* 1978, 73:725-6.
- [5] Jang G, Song JW, Kim HJ, Kim EJ, Jang JG, Cha SI: Foreign-body aspiration into the lower airways in adults; multicenter study. *PLoS One.* 2022, 17:e0269493. 10.1371/journal.pone.0269493.
- [6] Baharloo F, Veyckemans F, Francis C, Biettlot MP, Rodenstein DO: Tracheobronchial foreign bodies: presentation and management in children and adults. *Chest.* 1999, 115:1357-62. 10.1378/chest.115.5.1357.
- [7] Boyd M, Chatterjee A, Chiles C, Chin R Jr: Tracheobronchial foreign body aspiration in adults. *South Med J.* 2009, 102:171-4.
- [8] Tseng H.J., Hanna T.N., Shuaib W., Aized M., Khosa F., Linnau K.F. Imaging Foreign Bodies: Ingested, Aspirated, and Inserted. *Ann. Emerg. Med.* 2015; 66:570–582.e575. doi:10.1016/j.annemergmed.2015.07.499.
- [9] Ituntas B., Aydin Y., Eroglu A. Complications of tracheobronchial foreign bodies. *Turk. J. Med. Sci.* 2016; 46:795–800. doi: 10.3906/sag-1504-86.
- [10] Hewlett J.C., Rickman O.B., Lentz R.J., Prakash U.B., Maldonado F. Foreign body aspiration in adult airways: Therapeutic approach. *J. Thorac. Dis.* 2017; 9: 3398–3409. doi: 10.21037/jtd.2017.06.137.
- [11] Q.L. Shi, Q. Li, X.F. Shen.[Complicated airway foreign body in a child: a case report].*Lin Chuang Er Bi Yan Hou Tou Jing Wai Ke Za Zhi*, 32 (16) (2018),pp. 1276-1277, 10.13201/j.issn.1001-1781.2018.16.016.
- [12] J. Ng, S. Kim, B. Chang, et al. Clinical features and treatment outcomes of airway foreign body aspiration in adults, *J. Thorac. Dis.*, 11 (3) (2019), pp. 1056-1064, 10.21037/jtd.2018.12.130.
- [13] B.R. S, R. Md, M. N, et al. Aspirated almond masquerading as an obstructing endobronchial mass suspicious for lungcancer. *Case reports pulmonology*, 2018 (2018), 10.1155/2018/3742036.
- [14] P.A. Ricketti, D.W. Unkle, K.A. King, D.J. Cleri, A.J. Ricketti. A 15- year old girl with asthma and lower lobe bronchiectasis. *Allergy Asthma Proc.*, 36 (1) (2015), pp. 82-86, 10.2500/aap.2015.36.3784.